

PATIENT CASE REPORT

Acute Ischemic Stroke Follow-up

PRESENTATION:

76 year old Female presents to BRH via HCFR at 07:47 with decrease LOC and seizure like activity. Initial impression fentanyl overdose. Narcan x2 given with good LOC improvement and following commands, non focal neuro exam. Post treatment symptoms evolved into RT sided weakness with aphasia. TLKW witnessed at 07:10 patient w/in Alteplase window. IV Alteplase given at 09:47.

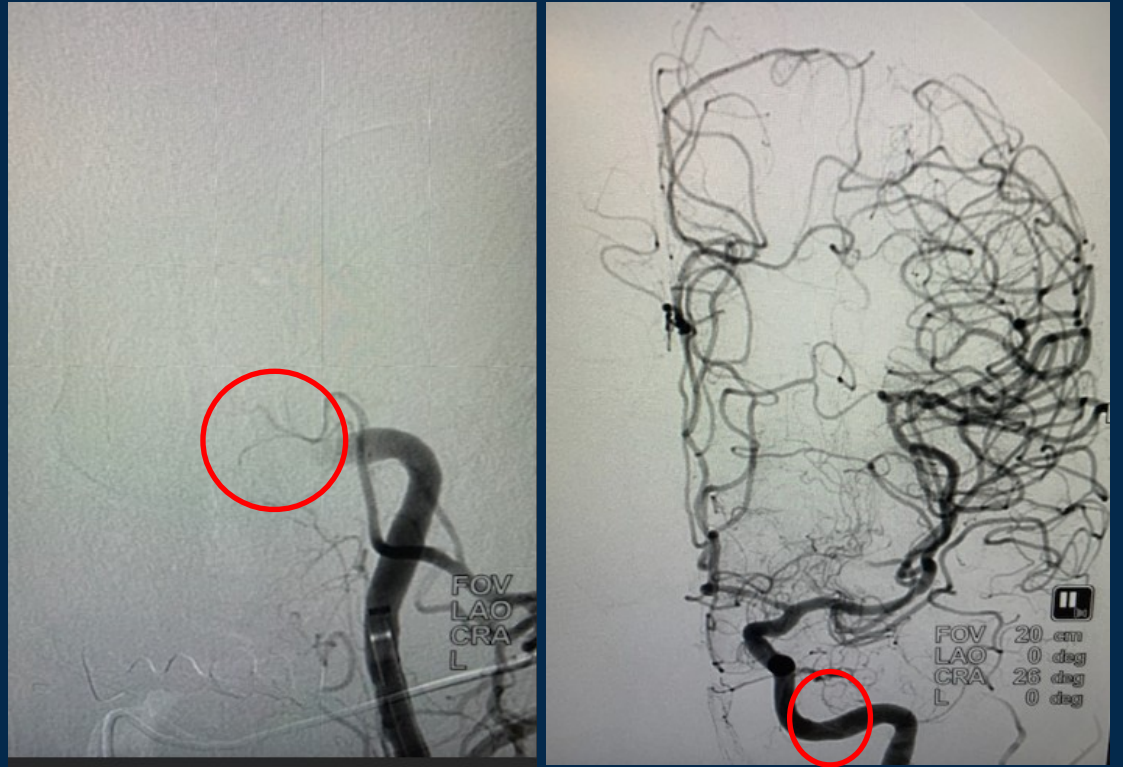
PROCEDURAL DESCRIPTION:

Clot Location: LICA, ACA, LMCA
Pre-Intervention flow: TIC1 0
Procedure: Patient in NIR at 10:45.
Groin puncture at 10:59. Reperfusion of Left cerebral hemisphere at 11:15

CASE CONCLUSION:

Door to Alteplase: 120 mins (stuttering s/s)
Door to Groin: 192 mins
Access to Revascularization: 16 mins
Post Intervention Flow: TIC1 2B

CASE IMAGES:



PATIENT CARE TEAM:

ED Physician: Dr. Villanueva ED: Collette, Alexis
Neurologist: Dr. Khan IR Team: Dr. Whisenant, Brett, Crystal, Heather, Chris

ONSET:
07:10

ARRIVAL:
07:47

NIR START:
10:59

REVASC:
11:15

TIC1 : 2B