

# PATIENT CASE REPORT

## Pipeline™ – Aneurysm Follow-up

PT WITH MULTIPLE PSEUDOANEURYSMS RECEIVES PIPELINE™ EMBOLIZATION DEVICE | BLOOD FLOW IS DIVERTED FROM THE ANEURYSM AND SYMPTOMS DISSIPATE

A Case Presented By: Justin Whisenant, MD

### PATIENT PRESENTATION

Pt is a 58 yo male. He had complained about dizziness and was admitted for further neurological testing. Pt has a history of seizure disorder, migraine headaches, and lumbago. Pt reports quitting smoking, no drug abuse, and no alcohol use. After additional testing the pt was diagnosed with multiple extracranial pseudoaneurysms.

### PROCEDURAL DESCRIPTION

**Location:** Two right proximal cervical vertebral (V4 segment) artery dissections with pseudoaneurysms. Large left cervical ICA dissecting pseudoaneurysm.

**Procedure:** Flow diverting stent placement for treatment under general anesthesia. Pipeline™ Embolization Device was used.

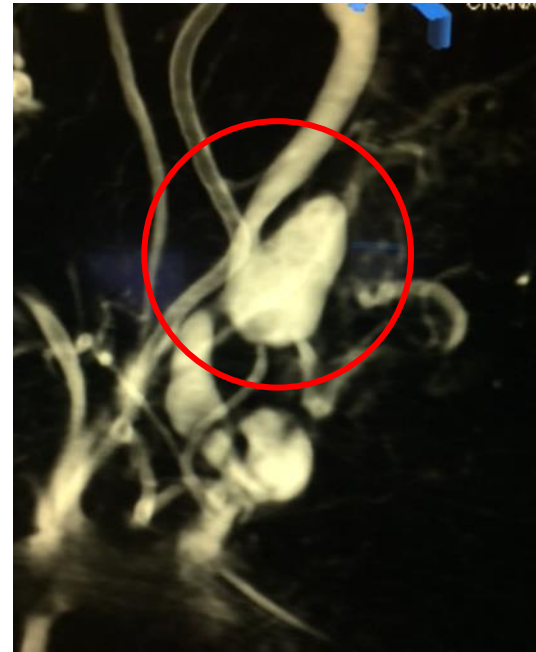**Medication:** Prior to procedure the pt was loaded with aspirin 650 and plavix 400 PO.

### CASE CONCLUSION

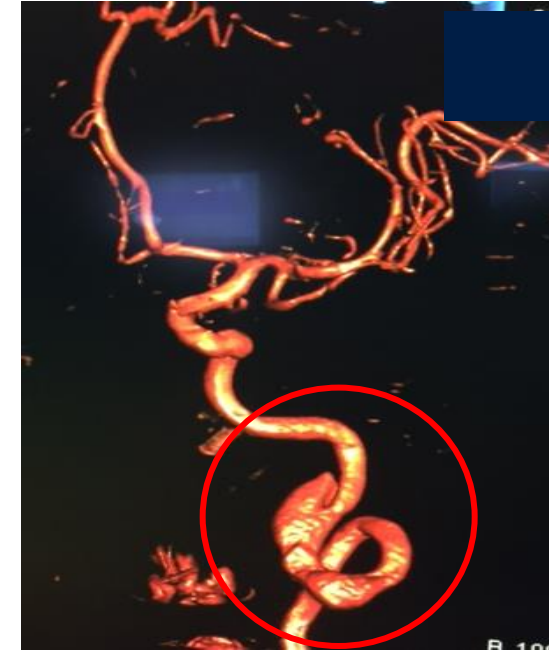Treatment of the aneurysms with flow diversion recommended to reduce rupture risk and to treat the posterior circulation ischemia (recurrent dizziness and left pontine enhancement).

### CASE IMAGES

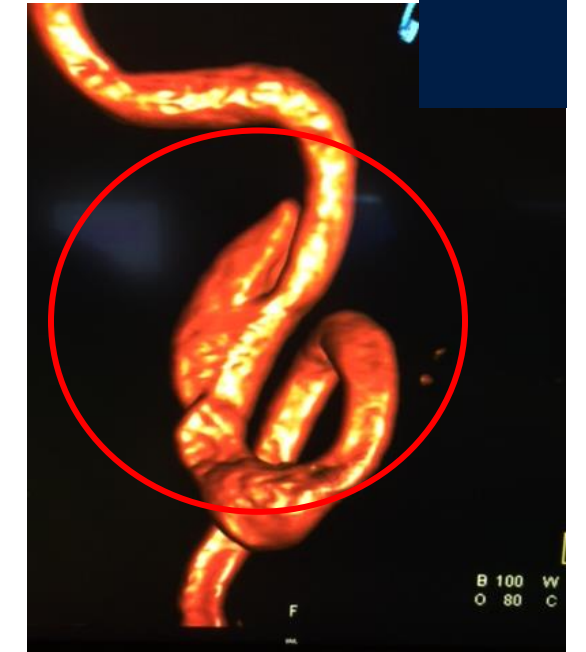
Pseudoaneurysm - Pre



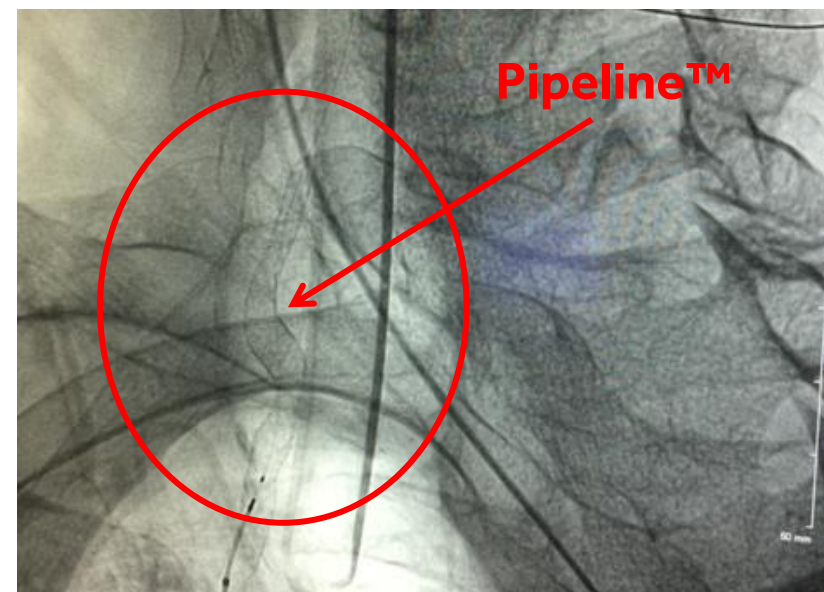
Pseudoaneurysm - Pre



Pseudoaneurysm - Pre



Pipeline™ Embolization Device Placement



Pseudoaneurysm – Post Procedure

