

PATIENT CASE REPORT

Pipeline™ – Aneurysm Follow-up

PT WITH MULTIPLE PSEUDOANEURYSMS RECEIVES PIPELINE™ EMBOLIZATION DEVICE | BLOOD FLOW IS DIVERTED FROM THE ANEURYSM AND SYMPTOMS DISSIPATE

A Case Presented By: Justin Whisenant, MD

PATIENT PRESENTATION

Pt is a 58 yo male. He had complained about dizziness and was admitted for further neurological testing. Pt has a history of seizure disorder, migraine headaches, and lumbago. Pt reports quitting smoking, no drug abuse, and no alcohol use. After additional testing the pt was diagnosed with multiple extracranial pseudoaneurysms.

PROCEDURAL DESCRIPTION

Location: Two right proximal cervical vertebral (V4 segment) artery dissections with pseudoaneurysms. Large left cervical ICA dissecting pseudoaneurysm.

Procedure: Flow diverting stent placement for treatment under general anesthesia. Pipeline™ Embolization Device was used.

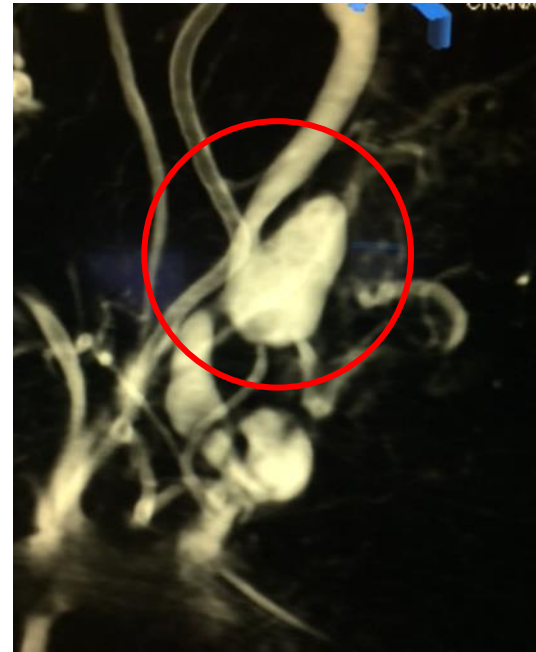Medication: Prior to procedure the pt was loaded with aspirin 650 and plavix 300 PO.

CASE CONCLUSION

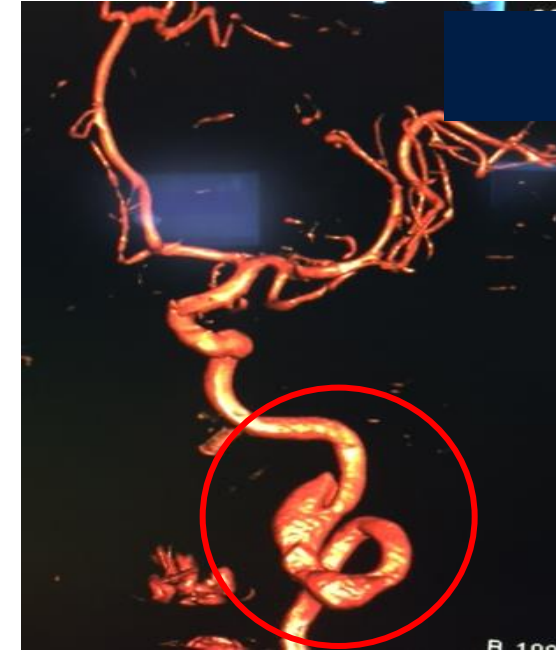
Treatment of the aneurysms with flow diversion recommended to reduce rupture risk and to treat the posterior circulation ischemia (recurrent dizziness and left pontine enhancement).

CASE IMAGES

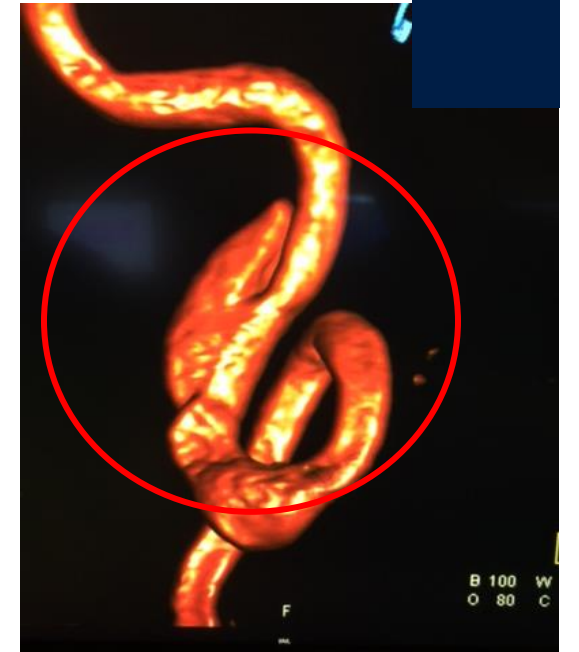Pseudoaneurysm - Pre



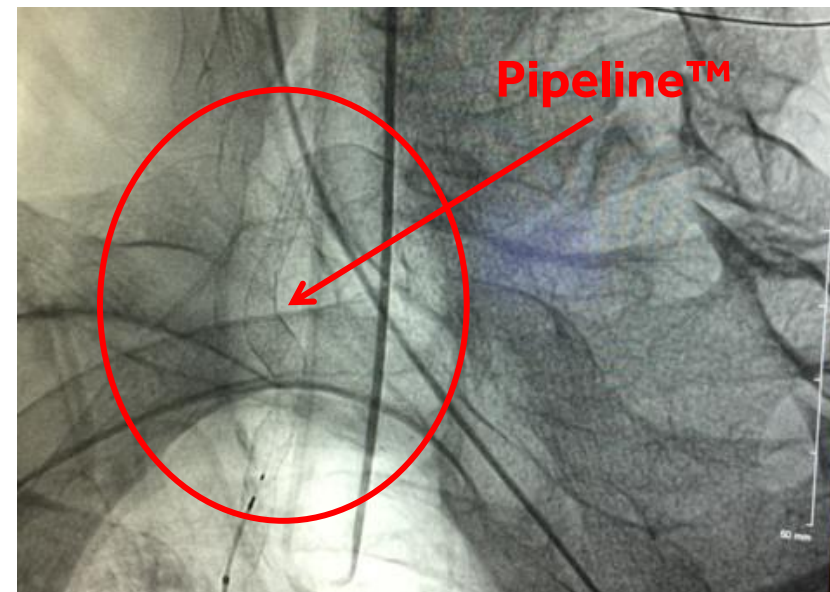
Pseudoaneurysm - Pre



Pseudoaneurysm - Pre



Pipeline™ Embolization Device Placement



Pseudoaneurysm – Post Procedure

