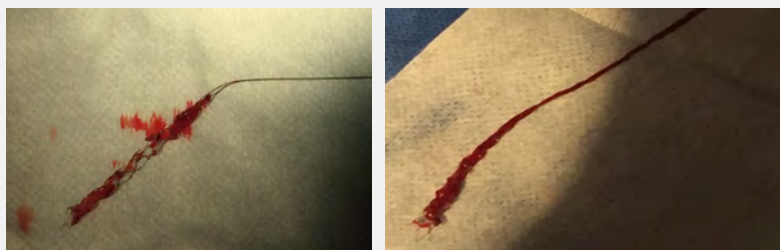

PATIENT OVERVIEW

- 49 year old male with past medical history including smoking and hyperlipidemia
- Presented with left-sided weakness and reported garbled speech at breakfast
- NIHSS: 11
- CT showed dense right MCA sign
- CTA of head showed occlusion of the Right ICA and MCA
- Patient received IV-tPA

CASE CONCLUSION

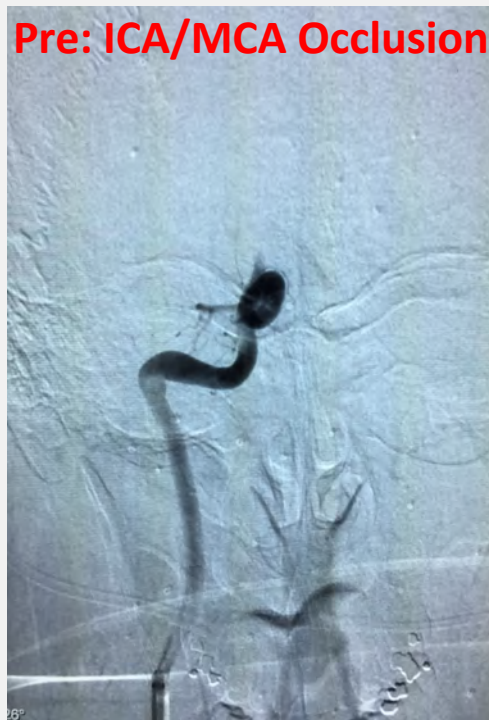- mRS 1
- Patient discharged post op day 2



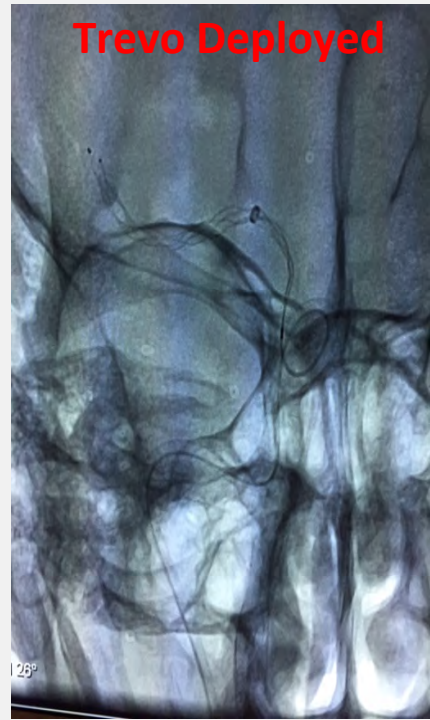
PROCEDURAL DESCRIPTION

- Angiography documented an occlusion of the Right Internal Carotid Artery & Middle Cerebral Artery
- An aspiration catheter was tracked into the right MCA and a microcatheter was tracked past the clot burden
- Two pulls of the stent retriever removed the thrombus from the ICA and MCA
- TICI 2B recanalization was observed

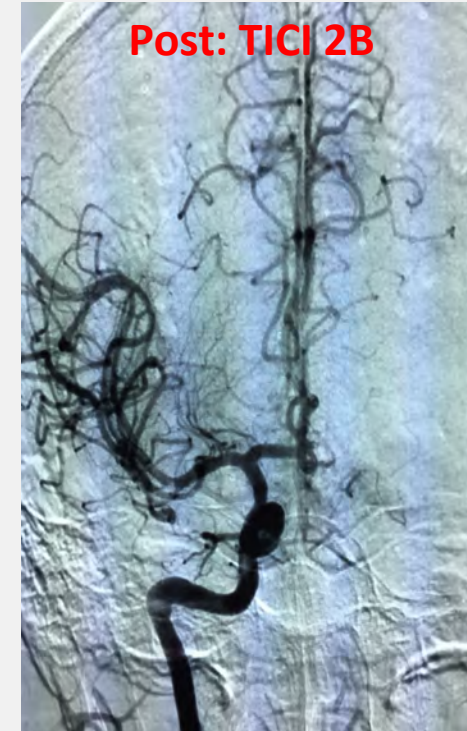
Pre: ICA/MCA Occlusion



Trevo Deployed



Post: TICI 2B



ED physician: Dr. Kwansa
Neurologist: Dr. Lisa Flaherty
EMS:

Referring Hospital: Citrus Memorial Hospital

Northside Hospital
6000 49th St North St.
Petersburg, FL 3370
(727) 521-4411