

PATIENT CASE REPORT

Acute Ischemic Stroke Follow-up

PT TRANSFERRED FROM CITRUS MEMORIAL TO NORTHSIDE |
FLOW IS RESTORED AFTER MECHANICAL THROMBECTOMY



Northside Hospital

PATIENT PRESENTATION

Male pt suffered an onset of stroke like symptoms at 11:45am. EMS transported the pt to Citrus Memorial Hospital where the patient presented with right sided weakness and slurred speech. The pt was a candidate for both tPA and embolectomy. Upon receiving tPA the pt was transported to NSH for mechanical intervention. He had an **NIHSS of 19**.

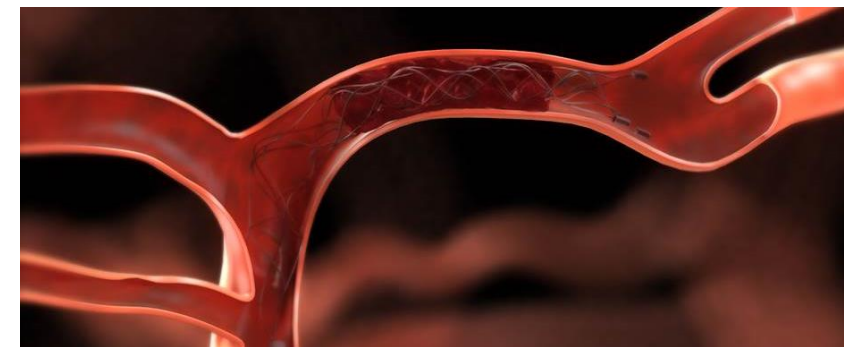
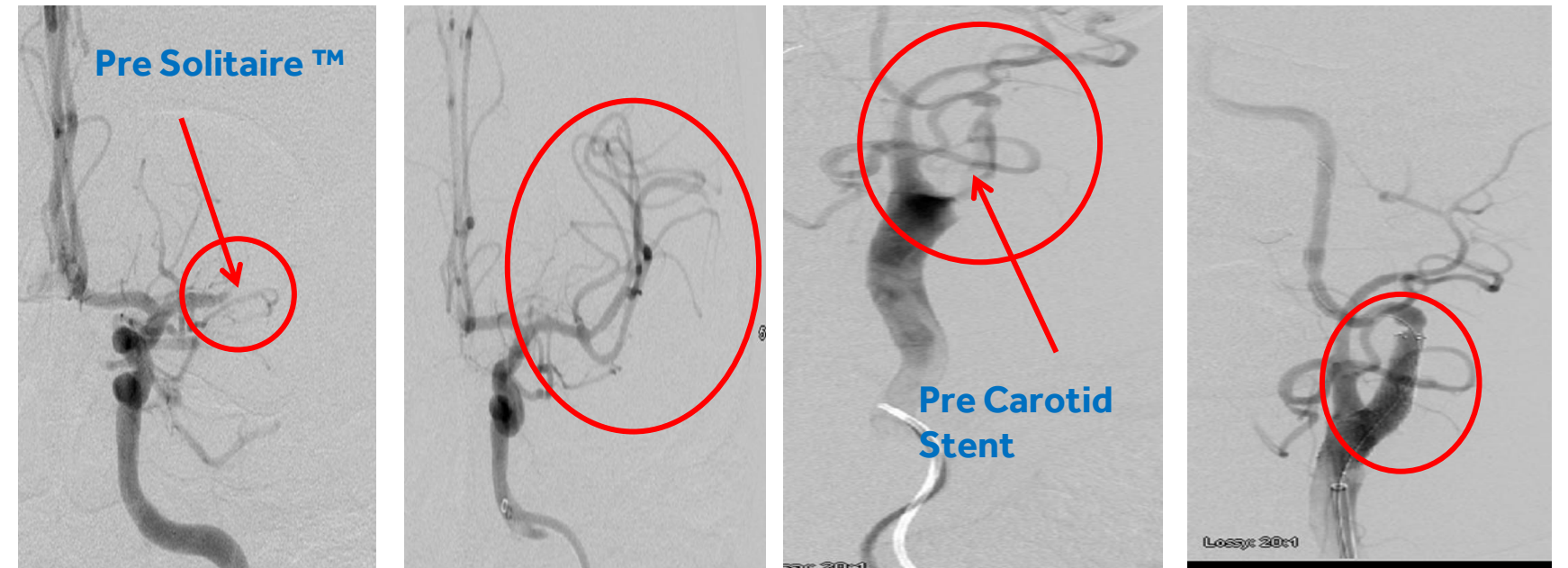PROCEDURAL DESCRIPTION

Clot Location: Left LICA and Left MCA
Pre Angio: TICl 0
Procedure: Pt arrived at NSH (3:04pm). Dr. Whisenant began intervention at 4:25pm. A Carotid Stent was used to open the LICA. Following the opening of the LICA a combination of aspiration and a Solitaire™ Device was used to remove the clot in the LMCA.
Post Angio: TICl 3

CASE CONCLUSION

Door to Groin: 81 minutes
Door to Revascularization: 206 minutes

CASE IMAGES



PATIENT CARE TEAM

Referral Hospital: Citrus Memorial Hospital
ED Physician: Dr. Hofstra
Neurologist: Dr. Matos
Anesthesia: Dr. Shenoy

Nurse: Caleb, RN
Intervention Tech: Travis, RT, Rebeka, RT
Interventionalist: Dr. Whisenant

